

## Rare Schwannoma Nerve Tumor in a Lesser Toe

### A Case Report

Anthony S. Jabra, DPM\*  
Johanna Godoy, DPM\*

A schwannoma is a solitary benign tumor composed of Schwann cells occurring anywhere in the peripheral nervous system. The diagnosis of a schwannoma is often difficult to make by clinical presentation and advanced imaging modalities. We present a case report of a 61-year-old Hispanic woman with a left-foot, third-digit, soft-tissue mass. The diagnosis of a schwannoma of the proper digital nerve was made postsurgically by means of histopathologic and immunohistochemistry parameters. This is a rare location for a schwannoma, and neurogenic tumor should be included in the differential diagnosis of soft-tissue mass, as there have been prior case reports. (J Am Podiatr Med Assoc 109(4): 322-326, 2019)

---

Schwannoma is a peripheral nervous system glial cell tumor derived from Schwann cells. The tumor is located within the myelin sheath. The tumor continues to grow, compressing the nerve fascicles within the sheath, resulting in symptoms.<sup>1-3</sup> Schwannomas are typically nonpainful tumors, and growth of the tumor is said to wax and wane.<sup>6</sup> Schwannomas are the most common benign nerve sheath tumor in the body and rarely affect the lower extremity, with reports ranging from 1% to 10%.<sup>3-5</sup> Schwannomas are well-encapsulated lesions, unlike neurofibromas. Specific etiologies of schwannomas are unknown, but prior reports suggest trauma as a potential origin.<sup>3</sup> The tumor does not have a gender predilection and can arise at any age, most often in the fourth decade of life.<sup>8</sup> The conservative treatment of choice is surgical excision. When excised completely, recurrence is unlikely, with minimal postoperative morbidity.<sup>9</sup> Care is taken not to damage the nerve fascicles when excising the tumor from nerve sheath, leaving the parent nerve anatomically intact.

In the present report, we describe a 61-year-old woman with a left-foot, third-digit conventional schwannoma of the proper digital nerve. Differential diagnosis performed preoperatively included mucoid/ganglion cyst, lipoma, giant cell tumor of tendon sheath, foreign-body granuloma, hamartoma, and peripheral nerve tumor. A definitive diagnosis was made following surgical resection,

and the patient performed well during the postoperative clinical course.

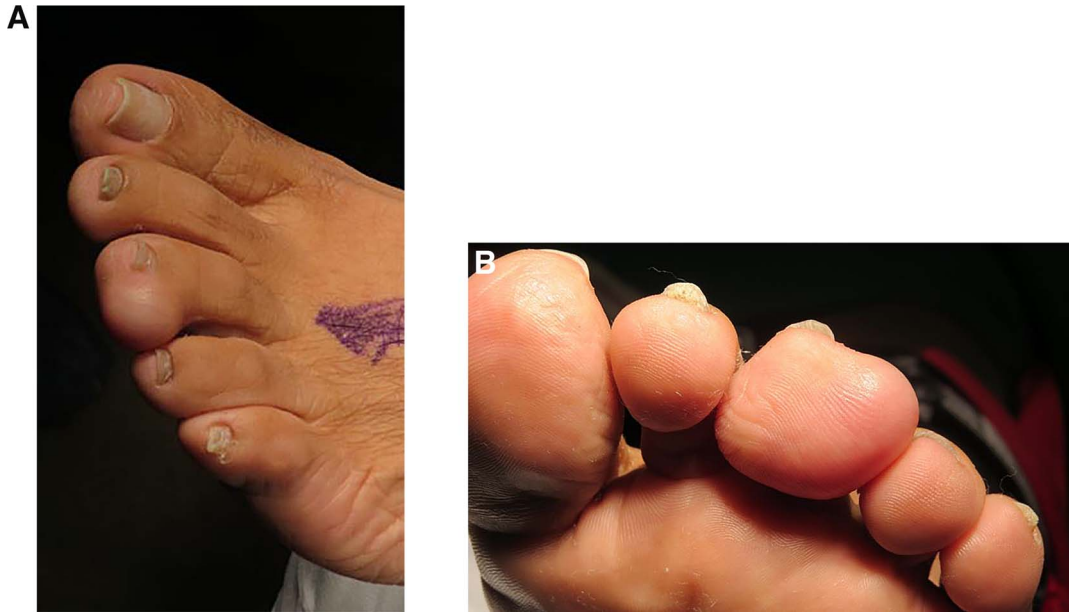### Case Report

A 61-year-old Hispanic woman presented to the clinic with concern regarding a soft-tissue mass of the third digit of her left foot. She noted that the soft-tissue mass had been present for approximately 3 years. She reported that the mass may have been secondary to “blood under the skin” caused by a vase that fell on her foot years ago. She denied current pain and admitted having local pain when the mass was compressed. Over the course of the previous 3 years, that mass increased progressively in size. She denied having other soft-tissue masses in her body. She had a medical history of stage 2 hypertension controlled with hydrochlorothiazide and lisinopril. Her family history was unremarkable for soft-tissue/bone tumor. A review of systems was noncontributing except for musculoskeletal examination. She had a normal vascular examination, and neurologic cutaneous sensation was intact. The biomechanical examination showed a flexible pes planus foot type without digital contractures on weightbearing. A dermatologic examination revealed a left third digit, plantar, immobile, oval, soft-tissue mass measuring 2.5 × 3.0 cm. Transillumination did not show that the mass was fluid filled. There was no callus or trophic changes to the involved digit. The mass was minimally tender to palpation during examination. The mass was nonvascular in origin by means of Doppler examination (Fig. 1).

---

\*New York College of Podiatric Medicine, New York, NY.

Corresponding author: Anthony S. Jabra, DPM, New York College of Podiatric Medicine, 53 E 124th St, New York, NY 10035. (E-mail: anthony.jabra@gmail.com)

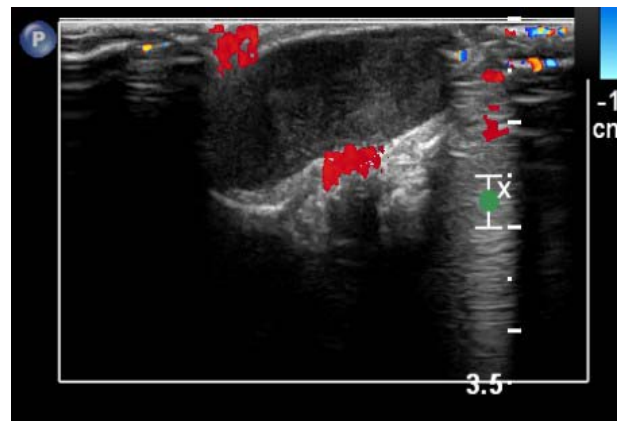


**Figure 1.** A, Dorsal surface of a left-foot, third-digit, soft-tissue mass. B, Plantar surface of a left-foot, third-digit oval mass demonstrating extension from lateral to medial.

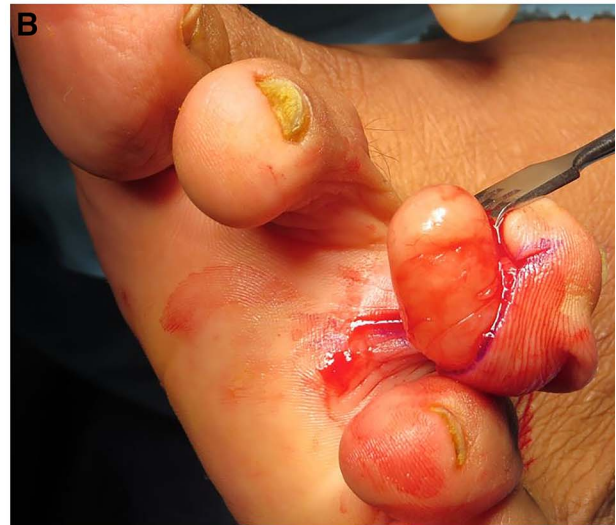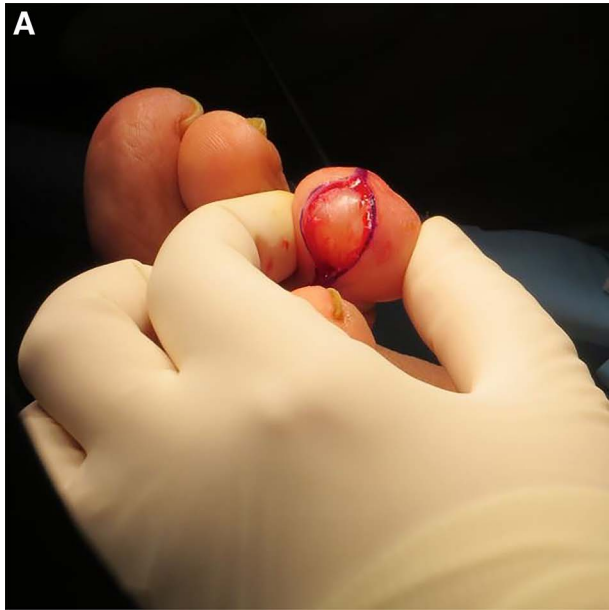
The patient underwent plain weightbearing radiography and ultrasound to the mass. The plain radiographs revealed a noncalcified soft-tissue mass without lucency and no bone periosteal reaction near the soft-tissue mass. Ultrasound examination revealed a  $2.4 \times 2.5 \times 1.1$ -cm oval mass that was homogeneously hypoechoic in echogenicity, with no vascular flow. The radiologist reported the mass to be benign in nature and possibly fluid filled, having a stalk to the flexor tendon. Differential diagnosis included ganglion cyst, giant cell tumor of tendon sheath, lipoma, foreign-body granuloma, hamartoma, and peripheral nerve tumor (Fig. 2).

She noted that, a few years ago, a physician at another institution attempted aspiration of the lesion but was unsuccessful. The patient was presented with treatment options and, because of an increase in the size of the soft-tissue mass, she opted for surgical excisional biopsy. Under intravenous sedation and local anesthesia digital V block, an excisional biopsy was performed. On sharp dissection to the epidermis using two converging semielliptical incisions to the plantar digital tuft and blunt dissection to subcutaneous tissue, the mass became immediately evident in the surgical field. The mass was noted to be encapsulated, and care was taken to ensure that the capsule was not violated (Fig. 3). Using sharp, blunt dissection, the mass was excised completely from surrounding soft tissue. The mass was then delivered for permanent pathologic examination. Intraoperatively, the mass

did not appear to be a ganglion cyst, as it was not fluid filled, nor did it appear to be a lipoma, because of gross fibrous consistency. The redundant skin was then excised with longitudinal converging semielliptical incisions with a length-to-width ratio of 3:1. The wound was flushed with copious amounts of sterile saline. The tourniquet was deflated, bleeding was controlled by electrocautery, and a single deep absorbable suture was placed to prevent hematoma formation. The skin edges were



**Figure 2.** Ultrasound image. The mass measures approximately  $2.4 \times 1.1 \times 2.5$  cm, is circumscribed and homogeneously hypoechoic, and is predominantly oval. No vascular flow of the mass is seen. These findings suggest a benign mass.



**Figure 3.** A, Surgical photograph with encapsulated mass. B, Using sharp, blunt dissection, the mass was excised completely from surrounding soft tissue.

coapted using nylon simple interrupted suture technique (Fig. 3).

The pathologic report indicated the mass to be a yellowish, encapsulated, bean-shaped, soft-tissue fragment measuring  $2.7 \times 1.2 \times 1.2$  cm and weighing 3 g. Histologically, examination revealed biphasic Antoni A and B areas and negative results for malignancy. The specimen was then evaluated with S100 protein immunostaining that was diffusely positive, supporting the diagnosis of schwannoma. Additional forms of immunohistochemical staining such as calretinin and CD34 were not performed. Diagnosis of schwannoma was differentiated from a neurofibroma because of an encapsulated tumor with palisaded nuclei representative of a Verocay body (Figs. 4 and 5).

The patient was able to walk in a surgical shoe postoperatively. At 2 weeks, the sutures were removed. She had intact cutaneous sensation with a 10-g Semmes-Weinstein monofilament. The postoperative course was uneventful, and the patient returned to sneaker shoe gear within 3 weeks.

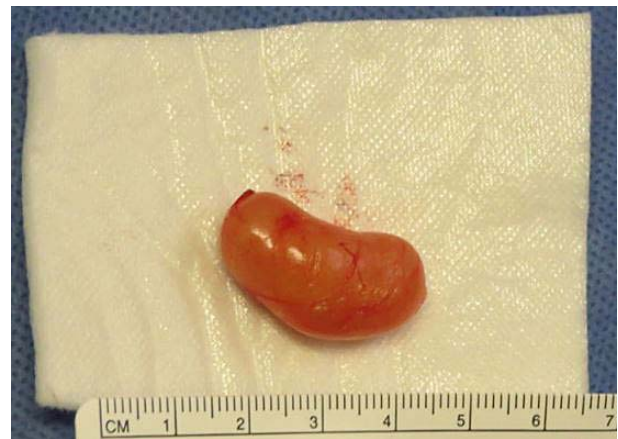## Discussion

The diagnosis of schwannoma is difficult clinically and radiographically. Clinically, our patient had localized pain, typical of that accompanying a space-occupying mass. She did not experience radiating paresthesia with percussion of the mass from nerve entrapment. Ultrasound of the schwan-

noma revealed a hypoechoic echogenicity resembling a fluid-filled lesion, such as a ganglion cyst.

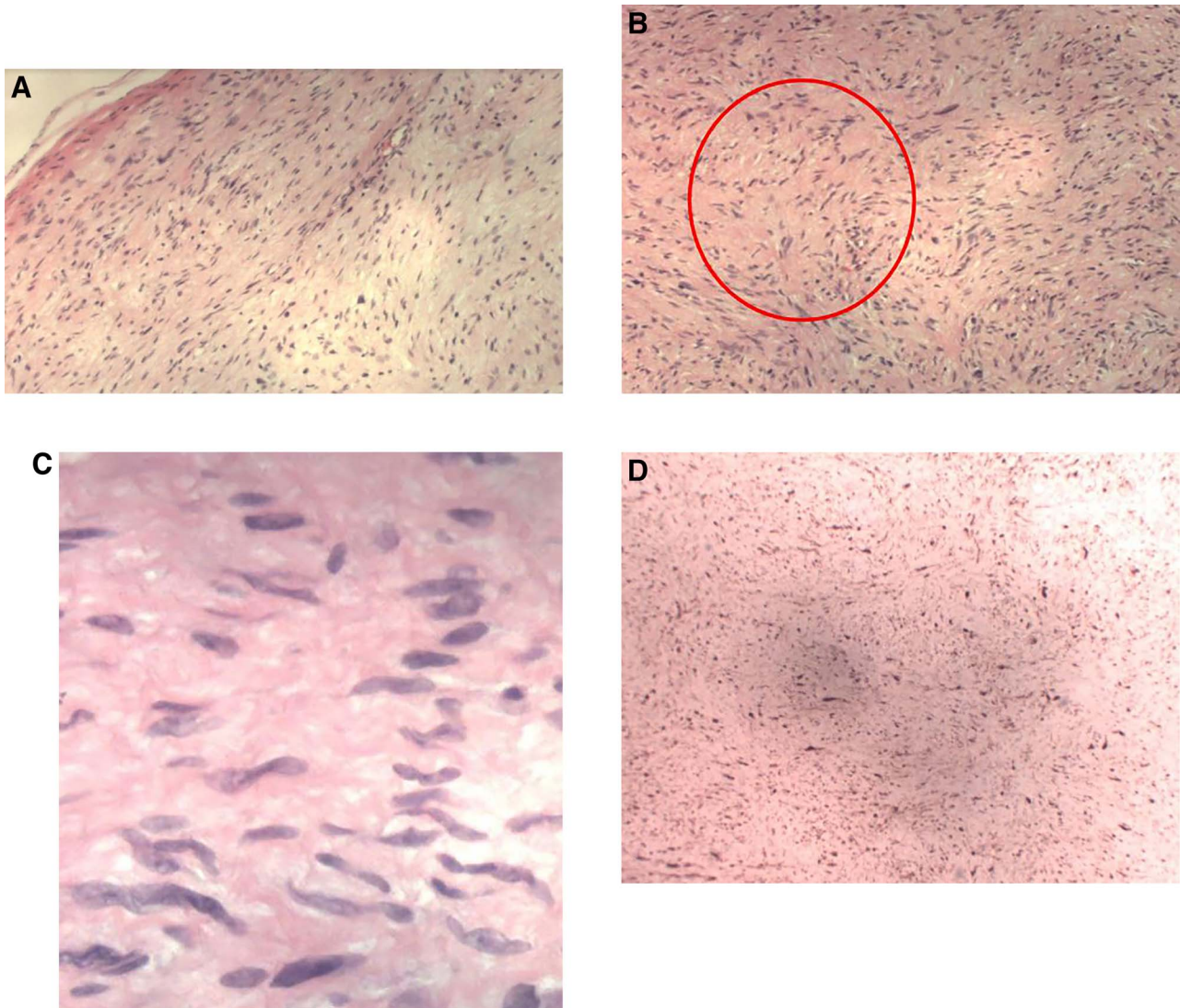
Only with surgical excision was the diagnosis confirmed. The gross appearance of schwannoma was a well-circumscribed mass with histologic hypercellular compact spindle (Antoni A) areas and hypocellular, microcystic areas (Antoni B). There are different variants of schwannoma, all with strong S100 protein uptake by immunohistochemistry.<sup>7</sup>

There have been previous reports of schwannoma on the dorsal digital surface. Golge et al<sup>11</sup> reported a  $3 \times 2$ -cm cellular schwannoma on the



**Figure 4.** The excised mass is  $2.7 \times 1.2 \times 1.2$  cm and weighs 3 g.





**Figure 5.** A, Circumscribed and encapsulated perineurium (H&E,  $\times 100$ ). B, Spindle cells and wavy nuclei arranged in short bundles with interlacing palisaded fascicles (red circle). Antoni A area (H&E,  $\times 100$ ). C, Verocay body showing a vertical row of palisading nuclei separated by acellular membrane in the Antoni A area (red circle) (H&E,  $\times 400$ ). D, Immunohistochemistry staining of S100 protein antibody demonstrating diffuse uptake into each nucleus.

dorsal side of the proximal phalanx of the right third digit that was locally destructive to adjacent bone. Ishida et al<sup>12</sup> reported a solitary erythematous tumor,  $25 \times 20$  mm in diameter and 10 mm in thickness, on the dorsal aspect of the distal interphalangeal joint of the second toe. Ly<sup>13</sup> reported a nonpainful flexor surface schwannoma that measured 2 cm of the interdigital nerve between the second and third metatarsal heads. All previous reports have similar lesion locations in the subdermal space, and the lesion resembled a ganglion cyst on all imaging modalities.

## Conclusions

We conclude that, although schwannoma in a digit is rare, there have been previous case reports of schwannomas affecting the forefoot, with similarities among the cases that may help practitioners with diagnosis. Previous reports of schwannomas are similar, and lesions are typically oval or bean shaped, locally painful to palpation with nonradiating pain, appear hypoechoic on ultrasound, and appear homogeneously isointense to muscle on T1-weighted images and hyperintense on T2-weighted images.<sup>10-13</sup> Surgical excision is the procedure of

choice. When excised completely, recurrence is unlikely, with minimal postoperative morbidity.<sup>9</sup> Schwannomas may resemble ganglion cysts by clinical presentation and radiographic modalities, and should be clinically suspected if the tumor is near a peripheral nerve. Diagnosis is typically made postsurgically by histopathologic and immunohistochemistry parameters. Differential diagnosis of soft-tissue masses is important, as it will help in preoperative surgical planning and ruling out malignancies.

---

**Acknowledgment:** Jagbir S. Sandhu, MD, pathologist at Metropolitan Hospital Center, for assistance in providing photomicrographs and details for a definitive diagnosis.

**Financial Disclosure:** None reported.

**Conflict of Interest:** None reported.

## References

1. FORTHMAN CL, BLAZAR PE: Nerve tumors of the hand and upper extremity. *Hand Clin* **20**: 233, 2004.
2. CARPINTERO P, GASCÓN E, ABAD JA, ET AL: Foot schwannomas that mimic nerve-entrapment syndromes. *JAPMA* **96**: 344, 2006.
3. KIM DH, MUROVICH JA, TIEL RL, ET AL: A series of 397 peripheral neural sheath tumors: 30-year experience at Louisiana State University Health Sciences Center. *J Neurosurg* **102**: 246, 2005.
4. MANGRULKAR VH, BRUNETTI VA, GOULD ES, ET AL: Unusually large pedal schwannoma. *J Foot Ankle Surg* **46**: 398, 2007.
5. MANGRULKAR VH, BRUNETTI VA, GOULD ES, ET AL: Unusually large pedal schwannoma. *J Foot Ankle Surg* **46**: 398, 2007.
6. MILLER TT, SOFKA CM, ZHANG P, ET AL: "Systematic Approach to Tumors and Tumor-Like Conditions of Soft Tissue," in *Diagnostic Imaging of Musculoskeletal Diseases*, edited by A Bonakdarpour, W Reinus, J Khurana, p 667, Humana Press, New York, NY, 2009.
7. WEISS SW, LANGLOSS JM, ENZINGER FM: Value of S-100 protein in the diagnosis of soft tissue tumors with particular reference to benign and malignant Schwann cell tumors. *Lab Invest* **49**: 299, 1983.
8. WEISS SW, GOLDBLUM JR: "Benign Tumors of Peripheral Nerves," in *Soft Tissue Tumors*, 4th Ed, p 1111, Mosby-Year Book, St. Louis, MO, 2001.
9. LAMBADE PN, PALVE D, LAMBADE D: Schwannoma of the cheek: clinical case and literature review. *J Maxillofac Oral Surg* **14**: 327, 2015.
10. KIM DH, RYU S, TIEL RL, ET AL: Surgical management and results of 135 tibial nerve lesions at the Louisiana State University Health Sciences Center. *Neurosurgery* **53**: 1114, 2003.
11. GOLGE U, KOMURCU E, KAYMAZ B, ET AL: An unusual location for cellular schwannoma. *J Coll Physicians Surg Pak* **24** (suppl): 46, 2014.
12. ISHIDA N, WATANABE D, YOKOO K, ET AL: Schwannoma of a digit. *Eur J Dermatol* **16**: 453, 2006.
13. LY P: Solitary benign schwannoma of the foot presenting clinically as a ganglion cyst: a case study. *JAPMA* **108**: 240, 2017.